

Quantification of Aortic Valve Stenosis Using Transesophageal Real-Time 3D Echocardiographic Images

F Veronesi¹, C Corsi¹, V Mor-Avi², L Sugeng²,
L Wienert², RM Lang², C Lamberti¹

¹DEIS, University of Bologna, Bologna, Italy

²University of Chicago Medical Center, Chicago, IL, US

Abstract

Aortic stenosis (AS) is the most common native valve disease. The assessment of its severity is routinely performed using transthoracic 2D echocardiography. In particular, aortic valve area (AVA) is usually assessed by continuity equation, although this measurement relies on geometrical assumptions, or by planimetry on transesophageal echocardiography. Accordingly, the aim of this study was to develop and test a new technique to assess the severity of AS using data acquired with real-time 3D matrix transesophageal echocardiographic (MTEE) probe. We studied 20 patients undergoing clinically indicated TEE. MTEE imaging was performed in 10 subjects with normal mitral and normal aortic valves and in 10 patients with moderate to severe AS (AVA < 1.4 cm²) and normal mitral valve. Our technique allowed quantitative volumetric measurements of dynamic AV parameters, and thus constitutes a new tool for objective assessment of the severity of AS.

1. Introduction

Aortic stenosis (AS) is the most common native valve disease. Its severity can be assessed by calculating aortic valve area (AVA) using catheter-based invasive measurements or echocardiography. Even if cardiac catheterisation using the Gorlin equation has been the gold standard for effective AVA assessment, 2D continuity equation using measurements extracted from transthoracic echocardiography is currently used in most instances as the standard for AS quantification. 2D transthoracic echocardiography with harmonic imaging has been used with some success for aortic valve planimetry, but it is less feasible than transesophageal echocardiography (TEE). Indeed, the multiplane TEE technique provides additional important information regarding the anatomy of the aortic valve and allows direct planimetric quantification of the anatomic AVA.

However, the accuracy of this semi-invasive method may be limited by difficulties in obtaining the correct cross-sectional view in which AVA is minimal. The use of reconstructed three-dimensional (3D) TEE has provided better results than standard TEE for AVA planimetry. However, this has not been widely adopted, partly because of the time-consuming off-line analysis [1]. Recently, transthoracic real-time 3D echocardiography (RT3DE), which allows spatial recognition of the anatomy and function of cardiac structures, has been used for the assessment of AVA [2-4]. These studies have demonstrated significant additional value, however manual tracing and manual cross-sectional plane selection are needed [2] and the method still relies on the continuity equation that has some limitation due to how velocities are computed and still have geometric assumptions [3].

The purpose of this study was to present an alternative semi-automatic non-invasive method to estimate AVA in patients with AS using new 3D matrix TEE imaging [5] that does not use continuity equation or require manual cross-sectional plane selection.

2. Methods

2.1. Data acquisition

The study protocol included 20 patients undergoing clinically indicated TEE. MTEE imaging was performed in 10 subjects with normal mitral valve (MV) and normal aortic valve (AV), and in 10 patients with moderate to severe AS (AVA < 1.4 cm²) and normal MV.

MTEE study were performed using the iE33 ultrasound imaging system (Philips Medical Systems) equipped with the fully sampled MTEE transducer (x7). This transducer utilizes approximately 3000 elements, in contrast to the 64 elements currently used in the multiplane TEE probe (Omni 3, Philips). Despite this difference in the number of elements, the sizes of the two transducer heads are comparable. The probe was

positioned at the mid-esophageal level at a 120° tilt. The scan volume in the wide-angled acquisition mode included the mitral apparatus, the aortic valve and proximal ascending aorta, while excluding the mid and apical ventricular segments to maximize frame rate. This full-volume mode uses ECG gating to merge 4 or 7 narrow pyramidal scans obtained over 4 or 7 consecutive heartbeats. To avoid stitch artifacts, special care was taken to stabilize the probe during data acquisition. Because stitch artifacts are easily recognizable in the 3D volume rendering mode in real time, the acquisition was repeated whenever obvious artifacts were noted.

2.2. Annulus initialization and tracking

Custom software was used to manually initialize the aortic annulus (AoA) in 3D space, and then to automatically track its motion frame-by-frame throughout the cardiac cycle.

First, two points on the AoA were manually initialized at end-diastole on a cut plane of the volume dataset. Then, the orthogonal plane crossing the center of the line connecting these two points was displayed, and two additional points were selected on the AoA. From these four points, the vector orthogonal to the AoA was automatically computed and used as the vertical axis of the AoA. Fifteen vertical cut planes passing through this axis (12° apart) were displayed one-by-one and two AoA points were identified on each plane. Using these additional points, the vertical axis of the AoA was recalculated. This allowed viewing of a series of cut planes parallel to the AoA, that represent the short axis views of the outflow tract, base of the aortic cusps, cusp coaptation point, inter-atrial septum, sinus of Valsalva and sino-tubular junction. The positions of the coaptation point and the inter-atrial septum were manually marked on the end-diastolic frame.

These AoA points were automatically tracked throughout the cardiac cycle and connected using three splines, one for each cusp in every frame. The inter-atrial point was used as reference position to identify the non-coronary aortic cusp, and then to identify the left and right cusps [6].

Finally, the AoA area projected on AoA basal plane was calculated throughout the cardiac cycle. From this measurement, the following parameters were extracted:

- 1) maximum AoA projected area;
- 2) minimum AoA projected area;
- 3) AoA area change (min – max AoA projected area)
- 4) AoA pulsatility defined as $(\text{AoA area change})/(\text{max AoA area}) \%$;

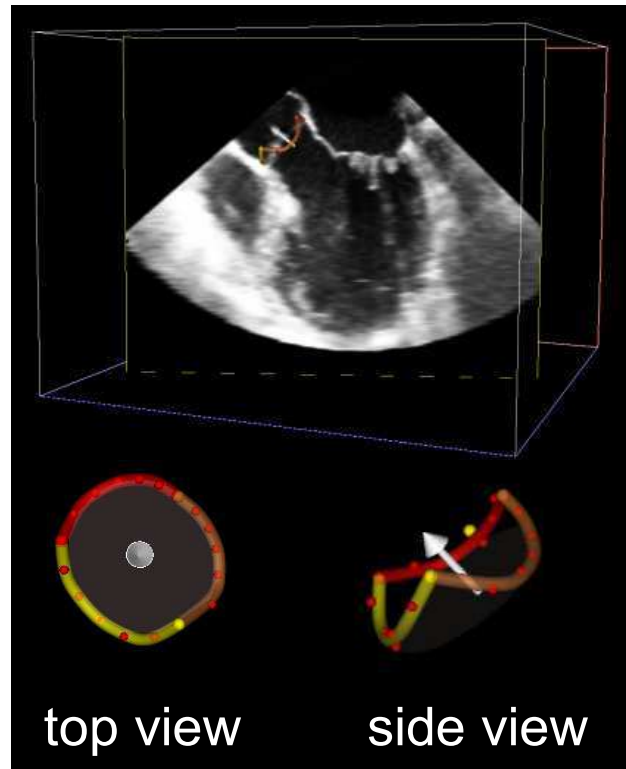


Figure 1. Top: Aortic annulus detected on 3D dataset. Bottom: Volume rendering of the detected AoA. Dots represent manually selected points and the colors differentiate among cusps. Note the crown shape of AoA on side view and projected AoA area on top view (light shading inside annulus). After detection the data is rotated in the direction of the arrow and cropped around the annulus.

2.3. AVA measurement

The tracked AoA was used to automatically compute the Maximum Intensity Projection (MIP) of the aortic valve excluding the surrounding structures. First, for each frame of the sequence, the data was rotated in the direction of the AV axis (arrow in figure 1). Then a parallelepiped portion of the data, including the whole AoA, was extracted. The result of this step is the 3D data in figure 2 (left).

MIP images (figure 2, right) were then computed in the vertical direction (AV axis), obtaining a 2D image for each frame in the cardiac cycle. These images were segmented to measure AV orifice (figure 2, bottom). Segmentation was performed using a flood-fill algorithm that allows the detection of connected pixels in an automatically identified gray level intensity range. This segmentation procedure allowed measurement of AVA throughout cardiac cycle and also the ratio between AVA and AoA area was computed.

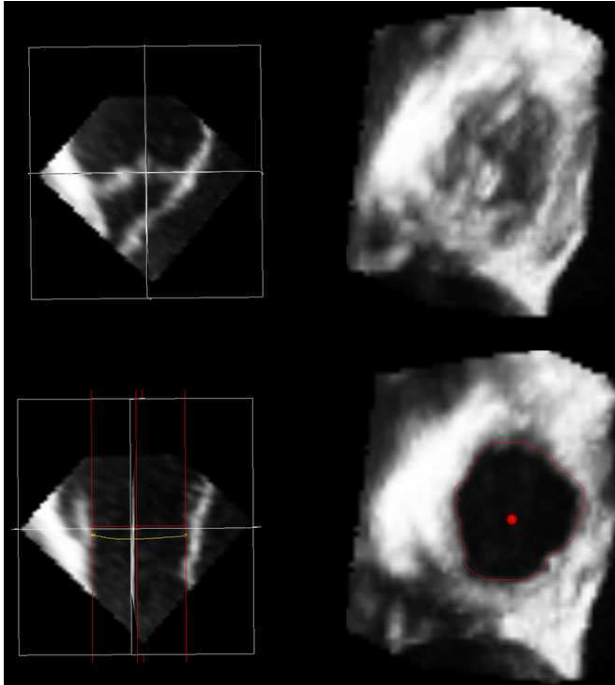


Figure 2. Left: Cross-sectional plane of data rotated and cropped according to detected AoA. Right: Maximum intensity projection (MIP) in AV axis direction. Bottom: Automatically segmented AVA (3.87 cm²) on vertical cross-sectional plane and on MIP image.

In patient with AS, AVA were also measured using conventional 2D continuity equation:

$$AVA = \frac{Area_{LVOT} * VTI_{LVOT}}{VTI_{AV}}$$

$$= \frac{(Diameter_{LVOT}^2 * 0.7854) * VTI_{LVOT}}{VTI_{AV}}$$

where LVOT diameter is computed from long-axis parasternal view, and VTI is velocity-time integral and is computed from Doppler flow data.

2.4. Statistical analysis

Computed parameters were averaged for all patients. Data were presented as mean ± SD. Significance of differences between parameters was tested using student's t-test.

3. Results

Quantitative results are presented in table 1. In patients with AS, AVA computed with our technique (0.94±0.28 cm²) showed good correlation with AVA computed from continuity equation (0.89±0.31; r=0.93), with a bias of 0.1 cm². In addition, while the maximum AoA area (during the first third of systole) was similar in both groups (NL: 5.0±1.3cm², AS: 4.8±1.2cm²), the maximum change in AoA area was significantly reduced in patients with AS (NL:23±7%, AS:13±4% of max AoA area).

Aortic Valve Area versus AoA projected area (Normal and AS)

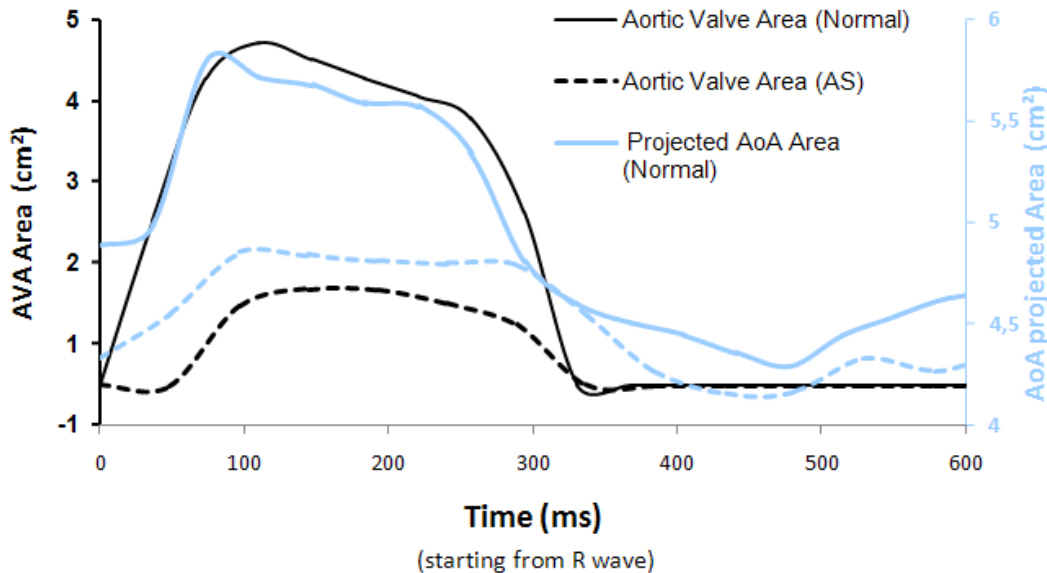


Figure 3. Time curves of AVA (black lines) and AoA projected area (light blue lines) throughout cardiac cycle. Dashed lines refer to a subject with AS while solid lined refer to normal subject. Note how the AoA projected area and AVA are correlated during ejection.

Also, AVA and AoA ratio were significantly different in the two groups (NL: 69±11%, AS: 25±11%).

Table 1. Measured parameters in normal (n=10) and AS (n=10) subjects

	AS	Normal	p value
Maximum AVA (cm ²)	1.1 ± 0.3	3.4 ± 0.6	<0.001
Mean AVA during ejection (cm ²)	0.94 ± 0.28	2.89 ± 0.63	<0.001
Ejection duration (ms)	269 ± 89	285 ± 57	<i>n.s.</i>
AVA, 2D continuity equation (cm ²)	0.89 ± 0.31	-	-
AoA Maximum area (cm ²)	4.8 ± 1.2	5.0 ± 1.3	<i>n.s.</i>
AoA minimum Area (cm ²)	4.2 ± 1.1	3.8 ± 1.0	<i>n.s.</i>
AoA change during cycle (cm ²)	0.6 ± 0.1	1.1 ± 0.5	0.002
AoA pulsatility % of max Area	13% ± 4%	23% ± 7%	0.002
AVA-AoA area ratio	25% ± 11%	69% ± 11%	<0.001

4. Discussion and conclusions

From the physiological point of view, our technique allowed the characterization on AV behaviour in AS patients compared to normal subjects. In particular, we found that AoA projected area and AVA are strictly correlated (figure 3). In case of AS, the ratio between AVA and AoA area is significantly reduced. This parameter reflects the ability of the AV to open and does not depend on AV size because it is normalized by AoA dimension. By analyzing AoA area throughout the cardiac cycle we also found that AS does not significantly affect 3D morphology of the AoA, but significantly modifies its dynamic behaviour by reducing AV ability to change size during ejection.

Our technique allows quantitative measurements of dynamic AV parameters in three dimensions, while fully exploiting the 3D nature of the MTEE data. In particular, AoA was identified in 3D and projected AoA area was computed. In addition, AVA were automatically measured throughout the cardiac cycle without using geometrical assumptions or continuity equation.

Moreover, this measurement does not require manual selection of an arbitrary cross-sectional plane, promising improved accuracy. These measurements correlated well with the standard 2D measurements computed using continuity equation. In conclusion, our methodology constitutes a new tool for objective assessment of the severity of AS.

References

- [1] Bernard Y, Meneveau N, Vuilleminot A, Magnin D, Anguenot T, Schiele F, Bassand JP. Planimetry of aortic valve area using multiplane transoesophageal echocardiography is not a reliable method for assessing severity of aortic stenosis. *Heart* 1997;78:68–73.
- [2] Goland S, Trento A, Iida K, Czer LS, De Robertis M, Naqvi TZ, Tolstrup K, Akima T, Luo H, Siegel RJ. Assessment of aortic stenosis by three-dimensional echocardiography: an accurate and novel approach. *Heart*. 2007;93:801-7.
- [3] Poh KK, Levine RA, Solis J, Shen L, Flaherty M, Kang YJ, Guerrero JL, Hung J. Assessing aortic valve area in aortic stenosis by continuity equation: a novel approach using real-time three-dimensional echocardiography. *Eur Heart J*. 2008;29:2526-35.
- [4] Gutiérrez-Chico JL, Zamorano JL, Prieto-Moriche E, Hernández-Antolín RA, Bravo-Amaro M, Pérez de Isla L, Sanmartín-Fernández M, Baz-Alonso JA, Iñiguez-Romo A. Real-time three-dimensional echocardiography in aortic stenosis: a novel, simple, and reliable method to improve accuracy in area calculation. *Eur Heart J*. 2008;29:1296-306.
- [5] Sugeng L, Shernan SK, Salgo IS, Weinert L, Shook D, Raman J, Jeevanandam V, Dupont F, Settlemier S, Savord B, Fox J, Mor-Avi V, Lang RM. Live 3-dimensional transesophageal echocardiography initial experience using the fully-sampled matrix array probe. *J Am Coll Cardiol*. 2008;52:446-9.
- [6] Veronesi F, Corsi C, Mor-Avi V, Sugeng L, Caiani EG, Weinert L, Lamberti C, Lang RM. Semi-Automatic Detection and Tracking of Mitral and Aortic Annuli from Real-Time 3D Transesophageal Echocardiographic Images. *Computers in Cardiology* 14-17 Sept. 2008:33-36.

Address for correspondence

Federico Veronesi
 Viale Risorgimento 2
 40136 Bologna, Italy
federico.veronesi@unibo.it