

Quantitative Assessment of the Effects of Annuloplasty on Mitral Annulus Dynamic Geometry Using Real-Time 3D Echocardiography

Laura Fusini¹, Federico Veronesi², Paola Gripari³, Francesco Maffessanti¹, Cristiana Corsi⁴, Francesco Alamanni^{2,3}, Marco Zanobini³, Moreno Naliato³, Gloria Tamborini³, Mauro Pepi³, Enrico G Caiani¹

¹Politecnico di Milano, Milan, Italy

²Università degli Studi di Milano, Milan, Italy

³Centro Cardiologico Monzino IRCCS, Milan, Italy

⁴Università di Bologna, Bologna Italy

Abstract

Mitral valve (MV) repair is the preferred treatment for mitral regurgitation associated with organic MV prolapse (MVP). Our goal was to describe the dynamic changes in mitral annulus (MA) geometry after annuloplasty, using custom software for MA tracking from transthoracic real-time 3D echocardiography (RT3DE). Forty-four MVP patients, divided into 2 subgroups (RIG and FLEX), were studied by RT3DE the day before, at 3 and 6 months after surgery. RT3DE was also obtained in 20 normal (NL) subjects. MA was tracked frame-by-frame and several parameters were computed. As expected, MVP had an enlarged MA and a reduced planarity compared to NL. Annuloplasty resulted in reduced area both in RIG and FLEX and in a more planar MA shape. Interestingly, at 3 and 6 months, FLEX height was greater than RIG, due to different ring design. This analysis gives new insights in the in-vivo performance of the implanted rings, offering a new tool in the clinical decision process and follow-up.

1. Introduction

The mitral annulus (MA) is a complex, dynamic, three-dimensional saddle-shape structure with the maximum height in the middle of the anterior part of the annulus near the aortic valve and another smaller peak in the mid of the posterior part [1]. This structure is important to normal mitral valve (MV) function as well as left ventricular and atrial performance.

Mitral regurgitation is one of the most common valvular heart diseases in modern clinical practice [2]. MV repair is the preferred treatment in patients with organic mitral valve prolapse (MVP). In fact, many studies have demonstrated that, when compared to replacement, MV repair leads to lower perioperative mortality and better postoperative LV function and long-

term survival [3,4].

The aims of this study were to describe the dynamic changes in MA geometry in pre-surgery MVP patients compared to normal subjects, and assess the dynamic morphology after MV repair with annuloplasty using two different type of ring, a complete rigid one and an incomplete flexible one, during a 6 months follow-up. This analysis was performed using custom software for MA tracking from transthoracic real-time 3D echocardiography (RT3DE) [5], that is the conventional imaging technique routinely utilized both for the diagnosis of MVP and for follow-up controls, thanks to the benefit of the third dimension in the visualization of cardiac valves [6,7].

2. Methods

2.1. Population

Forty-four patients (13 female, age 62±11 years) with severe organic mitral regurgitation due to degenerative MVP and ejection fraction (EF)>55% (biplane Simpson's rule from 2D echocardiographic data), with indications to MV surgical repair [3] were enrolled at the Centro Cardiologico Monzino, Milan. On the basis of the different implanted ring, these patients were divided into two subgroups:

1) 23 patients received a complete rigid ring (RIG, 5 female, age 54±13 years);

2) 21 patients an incomplete flexible ring (FLEX, 8 female, age 62±11 years).

Exclusion criteria were: EF<55%, associated MV stenosis, severe calcification of the MA, previous endocarditis, history of coronary artery disease, and cardiac arrhythmias. MV repair was considered successful only when the grade of residual mitral regurgitation was less than or equal to mild [8].

Furthermore, an age-matched group of 20 normal (NL) subjects (10 female, age 57 ± 9 years) was studied for comparison.

2.2. Echocardiography

The day before annuloplasty, a transthoracic RT3DE was performed using an iE33 scanner equipped with an X3-1 probe (Philips, Andover, MA). The same evaluation was repeated at 3 and 6 months after MV annuloplasty. Full volume acquisitions from the apical window were performed in the wide angle mode, in which ECG-triggered wedge-shape subvolumes were obtained over 4 to 7 consecutive cardiac cycles during a breath-hold (frame rate: 22-35Hz).

2.3. MV assessment

The transthoracic RT3DE were analyzed using custom software for the quantification of MA area and motion throughout the cardiac cycle [5]. After manual initialization of two points for each of 9 long-axis cut planes rotated around the MA center in the end-diastolic frame, the software automatically tracked frame-by-frame the MA profile in the 3D space using spline interpolation to link the MA points (Figure 1). From the detected annulus the 3D MA surface area was obtained by connecting with triangles adjacent MA points. Moreover, several parameters were computed to quantify MA morphology and dynamics:

- maximum and minimum MA surface area (A) during the cardiac cycle;
- delta area, defined as the absolute difference between

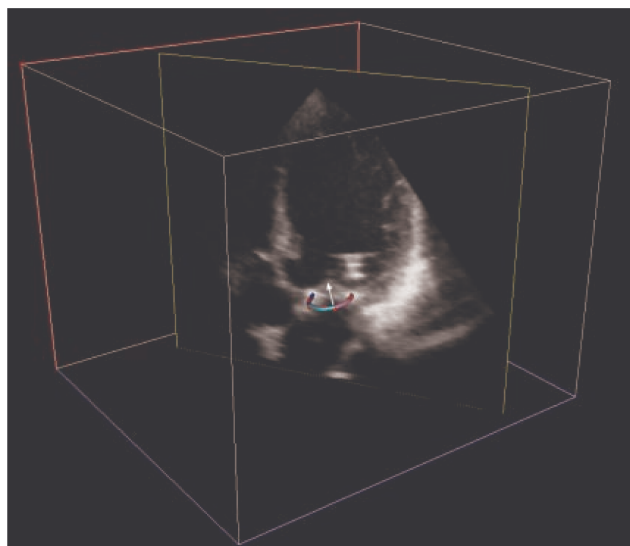


Figure 1. Example of a cut plane from a transthoracic RT3DE, obtained in a patient after annuloplasty, with the 3D reconstruction of mitral annulus superimposed.

maximum and minimum MA surface area ($\Delta A = \max A - \min A$);

- 2D projected MA area vs 3D surface area ratio (A_{2D}/A_{3D});
- longitudinal displacement (LD) of MA plane along the long axis direction, in respect to the end systolic position;
- mean height (H) in the cardiac cycle, computed in each frame as the difference between the saddle-horn and the lowest coordinate of MA points in the direction orthogonal to the MV plane;
- delta height, defined as the absolute difference between maximum and minimum H ($\Delta H = \max H - \min H$).

2.4. Statistical analysis

Data are presented as mean \pm SD. Results from the MVP group at pre-surgery were compared by unpaired t-test with those obtained from the NL population, used as reference. Moreover, for the RIG and the FLEX subgroup separately, to test for differences at 3 and 6 months after surgery, one-way ANOVA for repeated measure (with Holm-Sidak methods for multiple comparisons) was performed. For all tests, a p-value $< .05$ was considered significant.

3. Results

MA tracking was feasible in all RT3DE datasets. Mean time of analysis was about 20 minutes, including manual correction of the MA tracked points. In table 1, the results of the parameters extracted from 3D MA reconstruction in the control group and in the MVP group before surgery are reported.

Table 1. Results of mitral annulus dynamic analysis in normal subjects (NL, n=20) vs mitral valve prolapse patients (MVP, n=44).

	NL	MVP
maxA (cm ²)	10.7 \pm 1.7	18.6 \pm 4.8 *
minA (cm ²)	8.0 \pm 1.4	14.1 \pm 4.1 *
ΔA (cm ²)	2.7 \pm .9	4.5 \pm 1.8 *
A_{2D}/A_{3D}	.943 \pm .014	.950 \pm .025
LD (mm)	12.7 \pm 2.3	12.2 \pm 3.4
H (mm)	8.7 \pm 1.7	9.9 \pm 3.2
ΔH (mm)	5.1 \pm 1.8	7.3 \pm 3.6 *

*: p<0.05 NL vs MVP Pre-surgery, unpaired t test

As expected, MVP patients had an enlarged MA resulting in greater 3D surface area during the cardiac cycle compared to controls (MVP: maxA 18.6 \pm 4.8,

Table 2. Results of mitral annulus dynamic analysis in RIG (n=23) and FLEX (n=21) subgroups before surgery, at 3 and 6 months of follow-up.

	Pre-surgery		3-Months		6-Months	
	RIG	FLEX	RIG	FLEX	RIG	FLEX
maxA (cm ²)	18.9 ± 5.1	17.9 ± 4.7	5.0 ± .8 ‡	5.7 ± 1.5 ‡	4.7 ± .7 ‡	5.5 ± 1.4 ‡
minA (cm ²)	14.5 ± 4.7	13.7 ± 3.7	3.9 ± .5 ‡	4.6 ± 1.2 ‡	3.8 ± .6 ‡	4.5 ± .9 ‡
ΔA (cm ²)	4.4 ± 1.3	4.2 ± 1.6	1.1 ± .6	1.2 ± .5	.9 ± .5 ‡	1.0 ± .6 ‡
A _{2D} /A _{3D}	.947 ± .029	.953 ± .019	.978 ± .013 ‡	.947 ± .028	.982 ± .007 ‡	.946 ± .029
LD (mm)	12.9 ± 3.8	12.0 ± 3.2	8.7 ± 1.4 ‡	9.4 ± 2.1 ‡	9.7 ± 1.8 ‡	8.9 ± 2.1 ‡
H (mm)	10.3 ± 3.8	9.4 ± 2.6	3.4 ± .9 ‡	5.7 ± 1.9 ‡	3.0 ± .6 ‡	5.6 ± 2.2 ‡
ΔH (mm)	7.7 ± 4.0	6.5 ± 2.6	2.7 ± 1.2 ‡	3.3 ± 1.0 ‡	2.4 ± .9 ‡	3.2 ± 1.4 ‡

‡: p<0.05 vs Pre-surgery, One-way ANOVA for repeated measures

minA: 14.1±4.1; NL: maxA 10.7±1.7, minA 8.0±1.4). While no significant difference was found in MA longitudinal displacement in the two groups, an increased MA height in MVP revealed a greater non planarity compared to NL.

Table 2 shows the results obtained in the RIG and FLEX subgroup before annuloplasty, and at the 3 and 6 months follow-up. The procedure of annuloplasty, both with RIG and FLEX ring, resulted in reduced maximum and minimum value of 3D MA surface area during the cardiac cycle, associated with minimal ΔA compared to pre-surgical values. A more planar MA shape was also noticed, as depicted by a reduced H and an increased A_{2D}/A_{3D}. Interestingly, at 3 and 6 months after surgery, height in FLEX group was greater than in RIG, due to the lower planarity associated with incomplete ring design compared to the complete one. As consequence of the ring insertion, both complete and incomplete longitudinal displacement and height variations throughout the cardiac cycle were found decreased in the follow-up controls. At 6 months, all values were unchanged.

4. Discussion and conclusion

Several studies using 3D echocardiography focused on the evaluation of the MV and proposed different approaches to the geometrical description and quantification of MA after manual selection of two points on some long-axis cut planes [9-12]. In our study, we were able to automatically follow the MA points over the cardiac cycle and to obtain several MA morphological parameters.

Our results confirmed the non planar structure of the MA in normal subjects over the cardiac cycle. As expected, MVP patients had an enlarged MA with a greater variation of MA surface area throughout the cardiac cycle compared to controls, whereas longitudinal displacement was similar in MVP and in NL. In the follow-up monitoring, while MA area was significantly

reduced both in patients with a complete rigid ring and in those with incomplete flexible one, MA height was found lower in RIG group indicating a less non planarity.

In conclusion, MA dynamic analysis from RT3DE was feasible in MVP patients undergoing MV surgical repair with concomitant implanted annular prosthesis, both before surgery and during follow-up monitoring, as well as in normal subjects. This approach gives new insights in the in-vivo MA dynamic morphological changes and implanted annular prosthesis performance evaluation. This could constitute a new useful tool for support the surgeon in the clinical decision process and in follow-up monitoring. In fact, the 3D reconstruction of the MA morphology after annuloplasty could show the possible alterations over time due to the characteristics of the implanted device.

Acknowledgements

This study is part of the SurgAid project (www.surgaid.org), co-funded by the Italian Ministry of the University and Research (PRIN2007, Principal Investigator EG Caiani).

References

- [1] Fedak PW, McCarthy PM, Bonow RO. Evolving concepts and technologies in mitral valve repair. *Circulation* 2008;117:963-974.
- [2] Enriquez-Sarano M, Avierinos JF, Messika-Zeitoun D et al. Quantitative determinants of the outcome of asymptomatic mitral regurgitation. *N Engl J Med* 2005;352:875-883.
- [3] Bonow RO, Carabello BA, Chatterjee K et al. 2008 focused update incorporated into the ACC/AHA 2006 guidelines for the management of patients with valvular heart disease: a report of the American College of Cardiology/American Heart Association Task Force on Practice Guidelines (Writing Committee to revise the 1998 guidelines for the management of patients with valvular

- heart disease). Endorsed by the Society of Cardiovascular Anesthesiologists, Society for Cardiovascular Angiography and Interventions, and Society of Thoracic Surgeons. *J Am Coll Cardiol* 2008;52:e1-142.
- [4] Enriquez-Sarano M, Schaff HV, Orszulak TA et al. Valve repair improves the outcome of surgery for mitral regurgitation. A multivariate analysis. *Circulation* 1995;91:1022-1028.
- [5] Veronesi F, Corsi C, Sugeng L et al. Quantification of mitral apparatus dynamics in functional and ischemic mitral regurgitation using real-time 3-dimensional echocardiography. *J Am Soc Echocardiogr* 2008;21:347-354.
- [6] Lang RM, Mor-Avi V, Sugeng L et al. Three-dimensional echocardiography: the benefits of the additional dimension. *J Am Coll Cardiol* 2006;48:2053-2069.
- [7] Sugeng L, Chandra S, Lang RM. Three-dimensional echocardiography for assessment of mitral valve regurgitation. *Curr Opin Cardiol* 2009;24:420-425.
- [8] Irvine T, Li XK, Sahn DJ et al. Assessment of mitral regurgitation. *Heart* 2002;88 Suppl 4:iv11-iv19.
- [9] Ahmad RM, Gillinov AM, McCarthy PM et al. Annular geometry and motion in human ischemic mitral regurgitation: novel assessment with three-dimensional echocardiography and computer reconstruction. *Ann Thorac Surg* 2004;78:2063-2068.
- [10] Daimon M, Saracino G, Gillinov AM et al. Local dysfunction and asymmetrical deformation of mitral annular geometry in ischemic mitral regurgitation: a novel computerized 3D echocardiographic analysis. *Echocardiography* 2008;25:414-423.
- [11] Kwan J, Shiota T, Agler DA et al. Geometric differences of the mitral apparatus between ischemic and dilated cardiomyopathy with significant mitral regurgitation: real-time three-dimensional echocardiography study. *Circulation* 2003;107:1135-1140.
- [12] Watanabe N, Ogasawara Y, Yamaura Y et al. Mitral annulus flattens in ischemic mitral regurgitation: geometric differences between inferior and anterior myocardial infarction: a real-time 3-dimensional echocardiographic study. *Circulation* 2005;112:I458-I462.

Address for correspondence.

Enrico G Caiani, PhD
 Biomedical Engineering Department
 Politecnico di Milano
 Via Golgi 39, 20133, Milano, Italy
 caiani@biomed.polimi.it